

## Pancreatic metastases of renal cell carcinoma – case report

RC Shukla, R Pathak and S Senthil

Department of Radiodiagnosis and Imaging, BHU, Varanasi, India.

Corresponding author: Dr. Roshani Pathak, Department of radiodiagnosis and Imaging, BHU, India  
e-mail: drroshanipathak@yahoo.co.in

### ABSTRACT

Metastasis to the pancreas from renal cell carcinoma is distinctly uncommon. A solitary renal cell carcinoma (RCC) metastasis to the head of pancreas is rarely encountered. We present a 55 years old male who was admitted in our hospital with the complaint of abdominal pain on and off but more continuous since 15 days. He did not have any urinary symptoms. The laboratory tests were within the normal limits. Ultrasound of abdomen revealed an encapsulate mass in the kidney plus a mass in the head of pancreas, but no other distant metastases. On histopathological examination, sections of the renal mass showed features of a highly vascularized, clear cell neoplasm, with solid, nested, and alveolar architecture, consistent with RCC, clear cell type. Fine needle aspiration from the mass in the head of the pancreas confirmed the diagnosis of metastatic renal cell carcinoma, clear cell type. In the absence of widespread disease, pancreatic resection can provide long term survival in metastatic RCC, although few cases have been reported with lengthy follow up. The prognosis is better than for pancreatic adenocarcinoma.

**Keywords:** Pancreas, carcinoma, metastases.

Renal cell carcinoma (RCC) is a relatively rare adult solid tumour accounting for 3.0% of malignancies. The most common (70.0-80.0% of renal neoplasms) histological type of RCC is clear cell carcinoma. However, 30.0% of patients present metastatic disease at diagnosis and 20% locally advanced tumours.<sup>1</sup> Common sites of metastatic renal cell carcinoma are lymphnode, lung, bone, adrenals, liver, opposite kidney and brain.<sup>2</sup> Pancreatic metastasis of RCC origin is rare (1.5–3.0% of all metastatic RCCs).<sup>3</sup> According to the investigation of autopsy results by Tongio *et al*,<sup>4</sup> metastasis to the pancreas occurred in only 1.3% of 320 cases of renal cell carcinoma. Renal cell carcinoma usually leads to a solitary pancreatic metastasis, whereas multiple pancreatic metastases are uncommon.<sup>5</sup>

### CASE REPORT

A 55 years old male presented to our hospital with the complaint of abdominal pain on and off but more continuous since 15 days. He did not have any urinary symptoms. The laboratory tests were within the normal limits. Ultrasound of abdomen revealed an encapsulate mass in the upper pole of right kidney (Fig. 1) plus a mass in the head of pancreas (Fig. 2), but no other distant metastases. On histopathological examination (Fig. 3), sections of the renal mass showed features of a highly vascularized, clear cell neoplasm, with solid, nested, and alveolar architecture, consistent with RCC, clear cell type. Fine needle aspiration from the mass in the head of the pancreas confirmed the diagnosis of metastatic renal cell carcinoma, clear cell type. The tumour of the

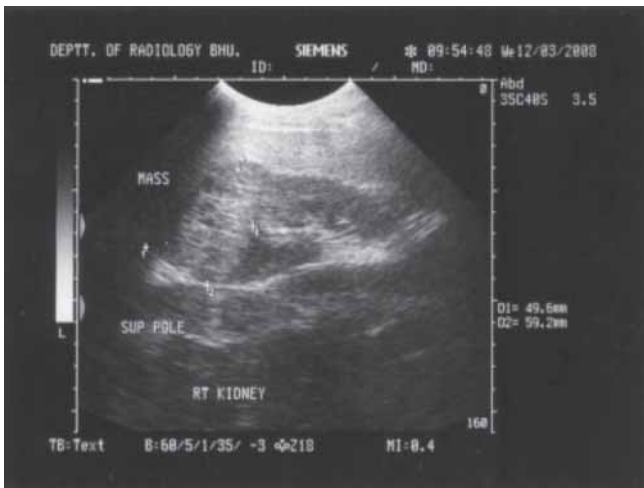
kidney was asymptomatic in this case where as the patient presented with the symptoms produced by the metastatic deposit to the pancreas.

### DISCUSSION

Renal cell carcinoma accounts for 2.0–3.0% of all malignant tumours in adults.<sup>5</sup> RCC usually gives metastases in lungs, bones, lymphnodes and cerebrum but other less common metastatic sites such as the pancreas, duodenum, spinal canal, thyroid, testis and small intestine, have also been reported.<sup>6</sup> RCC produce pancreatic metastases in 2.8% of cases.<sup>7</sup> In a review of literature, only 96 cases have been reported, most of which regarding solitary metastasis associated with the presence of metastases in other regions of the body. Metastases do not have a predilection for a particular part of the pancreas. Pancreatic metastases have a favourable outcome compared with primary pancreatic cancer.<sup>5</sup>

Metastatic RCC may be the first manifestation of the disease, even masquerading as a primary pancreatic neoplasm. In a series studied by Thompson *et al*,<sup>8</sup> the metastatic focus was the initial presentation of the RCC in four of the cases, and, in one case, it took 13.2 years before the primary RCC finally was removed.

Pancreatic metastases from renal cell carcinoma are often asymptomatic in more than 50.0% of cases.<sup>9</sup> Most patients with secondary pancreatic tumours present in a similar way to those with primary tumours. The symptoms described are abdominal pain, weight loss,



**Fig. 1.** Abdominal Ultrasonography: Renal cell carcinoma in the upper pole of right kidney.

gastrointestinal bleeding, anaemia and jaundice. There may be an abdominal mass and pancreatic dysfunction but some patients have no symptoms et al.<sup>3</sup>

There usually is no retropancreatic fat obliteration. When it is present, the obliteration of the fat suggests a pancreatic primary tumor or direct continuity from the lymph nodes, as may be seen with a lymphoma.<sup>8</sup> Metastatic lesions in the pancreas may occasionally be identified by Endoscopic Ultrasound-guided Fine needle aspiration (EUS-FNA) in patients with a simultaneous primary or a remote history of malignancy. Several small series have documented that a low postoperative mortality with excellent long-term survival can be achieved for resection of focal pancreatic metastases. Therefore, preoperative diagnosis of secondary pancreatic involvement by systemic malignancy may permit consideration of surgical management in these patients. Traditionally, percutaneous FNA is used for the diagnosis of pancreatic masses, and the diagnosis of pancreatic metastases by this method has been reported. When available, however, EUS has largely supplanted percutaneous FNA for the sampling of solid pancreatic masses, including pancreatic metastases. In a recent report of 11 patients with metastatic RCC to the pancreas, Be'chade et al found that 10 had well-defined borders. Therefore, it appears that EUS visualization of a welldefined pancreatic mass in a patient with a history of malignancy should raise suspicion for a metastatic lesion.<sup>10</sup> The recognition of metastatic foci in most tumors is important clinically, because metastases usually implies a poor prognosis, with the exception of a few tumors, such as RCC.

It is peculiar that RCCs are known to develop late and/or solitary metastases. Moreover, a solitary metastasis from RCC occurs with an incidence rate of around 1.0–

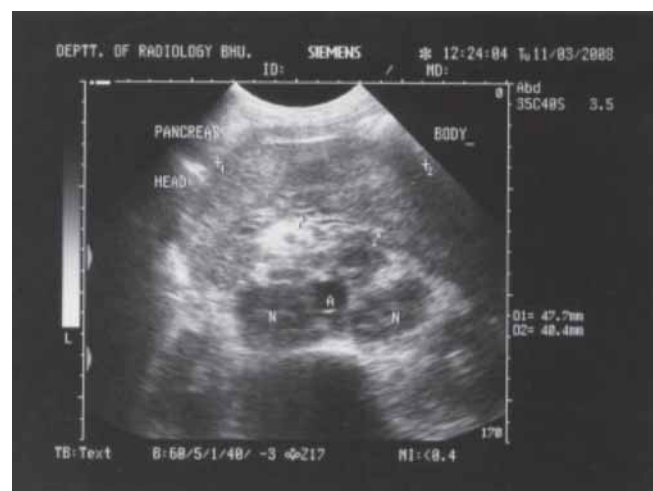4.0%, of which about 1.0–2.0% are recognized to occur in the pancreas.<sup>8</sup>

Although metastatic foci are present in about 25.0% of RCCs at the time of primary diagnosis (synchronous), metastatic disease can develop as part of the latency of the tumor, with delayed development of metastases after many years of dormancy (metachronous), especially if the tumor is well- differentiated.<sup>9</sup>

Metastases are solitary in fewer than 10.0% of patients with metastatic renal cell cancer. Resection of isolated metastases may contribute to prolonged survival in a small subgroup of these patients. More than 50 cases of pancreatic resections for metastatic renal cell cancer have been reported, and it would appear that these are the most frequent surgically treated metastases to the pancreas. More than 80.0% of the patients undergoing pancreatectomy survive longer than 12 months and 5-year survival of 31.0% has been predicted for patients undergoing resection of pancreatic metastasis due to renal cell carcinoma. This survival is even better than that of patients with resected primary pancreatic adenocarcinoma, for whom 5-year survival is between 15.0% and 20.0%.<sup>11</sup>

There are several factors affecting survival of patients with metastases of RCC: the site and number of foci, the performance status of the patient and the disease-free interval.<sup>12</sup> In large series mean time from radical nephrectomy to pancreatic recurrence in RCC was 8 to 12 years.<sup>13</sup> Several authors have documented long-term survival after surgical metastatectomy in RCC.<sup>1</sup>

Metastases in pancreas are suspected on the CT appearance of hyper-vascular lesion and should be further evaluated with endoscopic sonography and biopsy. A primary tumour of renal cell origin should be



**Fig. 2.** Abdominal Ultrasonography: Renal cell carcinoma metastases in pancreatic head.



**Fig. 3.** Microscopic picture of renal cell carcinoma metastases in pancreas.

suspected on any abnormality noted in kidneys on imaging in the presence of metastatic lesion in pancreas. When metastases are limited to the pancreas, surgery can provide 31.0% 5-year survival rate. The lesions are multifocal in 30.0% of patients and resectable in 80.0% of cases. Overall there is an excellent prognosis for RCC patients with surgical resection of pancreatic metastases depending on their general state of health.<sup>9</sup>

#### REFERENCES 1

1. Martel CL, Lara PN. Renal cell carcinoma: current status and future directions. *Critical Rev in Oncol/Hematol* 2003; 45: 177-90.
2. Stankard CE, Karl RC. The treatment of isolated pancreatic metastases from renal cell carcinoma: a surgical review. *Amer J gastroenterol* 1992; 87: 1658-60.
3. Zacharoulis D, Asopa V, Karvounis E, Williamson RCN. Resection of renal metastases to the pancreas: a surgical challenge. *J Int'l Hepatopancreato Biliary Assoc (HPB)* 2003; 5: 137-41.
4. Kobayashi A, Yamaguchi T, Ishihara T. Spontaneous Rupture of Pancreatic Metastasis from Renal Cell Carcinoma. *Japanese J Clin Oncol* 2004; 34: 696-9.
5. Ascenti G, Visalli C, Genitori A, Certo A, Pitrone A, Mazziotti S. Multiple hypervascular pancreatic metastases from renal cell carcinoma Dynamic MR and spiral CT in three cases. *J Clin Imaging* 2004; 28: 349-52. Ascenti11
6. Papachristodoulou A, Mantas D, Kouskos E, Hatzianastassiou D, Karatzas G. Unusual presentation of renal cell carcinoma metastasis. *Acta Chir Belg* 2004; 104: 229-30.
7. Robbins EG, Franceschi D, Barkin JS. Solitary metastatic tumors to the pancreas: a case report and review of the literature. *Amer J Gastroenterol* 1996; 91: 2414-7.
8. Thompson LDR, Heffess CS. Renal cell carcinoma to the pancreas in surgical pathology material. *Cancer* 2000; 89: 1076-88.
9. Ninan S, Jain PK, Paul A, Menon KV. Synchronous pancreatic metastases from asymptomatic renal cell carcinoma. *J Pancreas (Online)* 2005; 6: 26-8.
10. DeWitt J, Jowell P, LeBlanc J. EUS-guided FNA of pancreatic metastases: a multicenter experience. *Gastrointestinal Endoscopy* 2005; 61: 689-96.
11. Zgraggen K, Castillo CF, Rattner DW, Sigala H, Warshaw AL. Metastases to the pancreas and their surgical extirpation. *Arch Surg* 1998; 133: 413-8.
12. Giuliani L, Giberti C, Martorana G, Rovida S. Radical extensive surgery for renal cell carcinoma: long-term results and prognostic factors. *J Urol* 1990; 143: 468-73.
13. Kassabian A, Stein J, Jabbour N, Parsa K, Skinner D, Parekh D, Cosenza C, Selby R. Renal cell carcinoma metastatic to the pancreas: A single-institution series and review of the literature. *Urol* 2000; 56: 211-5.