

## Single burr hole drainage for chronic subdural haematoma

NK Khadka, GR Sharma, YB Roka, P Kumar, P Bista, D Adhikari and UP Devkota

National Neurosurgical Referral Centre, National Academy of Medical Sciences, Bir Hospital, Kathmandu, Nepal

**Corresponding author:** Dr Nilam Kumar Khadka, MCh Neurosurgery, National Neurosurgical Referral Centre, National Academy of Medical Sciences, Bir Hospital, Kathmandu, Nepal

### ABSTRACT

Chronic subdural haematoma is a common neurosurgical condition and surprisingly surgical treatment ranges from twist drill craniostomy to more radical membranectomy. However, the outcome is generally favourable with appropriate therapy. This retrospective study is aimed at analyzing the result of single burr hole drainage of such haematoma under local anaesthesia over a period of fifteen years. There were a total of 365 patients ranging from 6 months to 89 years with the mean age of 60 years. Recurrence of haematoma was noted in 17 (4.6%) patients and majority of them (65.0%) were managed by aspiration through the previous burr hole. Favorable outcome was noted in 98.6% patients. Those with adverse outcome were in coma preoperatively. This study suggests that single burr hole drainage under local anaesthesia is sufficient in the majority of patients and outcome was favorable even in the elderly provided they presented before lapsing into coma.

**Key words:** Chronic subdural, haematoma, local anaesthesia, burr hole.

### INTRODUCTION

Virchow first proposed chronic inflammation of the meninges as being the cause of a chronic subdural haematoma.<sup>1</sup> In 1914, Trotter suggested trauma as the etiological factor.<sup>2</sup> Majority of the symptomatic chronic subdural hematoma need evacuation and the surgical procedure advocated exhibits a spectrum ranging from twist drill craniostomy (TDC) to craniotomy and membranectomy.<sup>3,4</sup> Majority, however, favour multiple burrhole drainage. The present retrospective study analyzed the results of single burr hole drainage (BHD) under local anaesthesia without using postoperative subdural drain.

### MATERIALS AND METHODS

This is a retrospective study of 365 patients who underwent single burr hole drainage under local anaesthesia for chronic subdural haematoma (CSDH) over a period of 15 years (July 1989 to July 2004) at a tertiary referral hospital in Nepal. The data were collected from the patients' files, operation theatre records, hospital discharge summaries. Diagnosis was confirmed by cranial computed tomography (CT) scan and the clinical status was assessed in terms of Glasgow Coma Scale (GCS). Minimally symptomatic patients with normal GCS and without mass effect in CT were treated conservatively. Similarly, children who only required needle aspiration were excluded from the study. Patients with bilateral hematoma were considered as a single case. All were operated under local anaesthesia except children and comatose adults who were given general anaesthesia. The hematoma was drained through

a single dependent burr hole and the subdural space was irrigated with normal saline using a red rubber catheter until the effluent returned clear. The head was then rotated, the cavity was filled with normal saline and the burr hole was closed without inserting a subdural drain. The patients who revealed failure of primary cerebral expansion prior to the end of wound closure or exhibited obviously thick outer membrane were put on systemic dexamethasone. Postoperatively, the patients were adequately hydrated, nursed in the flat position and allowed ambulation only after 48 hours. Prophylactic antibiotics were not used and the use of anticonvulsants was restricted only to those who had previous seizure. Outcome was assessed in terms of Glasgow Outcome Score (GOS) at three weeks and the patients in category 4 or 5 were defined as having favorable outcome. CT scan was repeated only in those who either did not recover or deteriorated.

### RESULTS

Of the 365 patients, there were 307 (84.0%) males and 58 (16.0%) females with the mean age of 60 years (22-96 years) (Fig-1) Characteristics of study population are given in Table-1. Important preoperative clinical findings are summarized in Table-2.

There were 365 (94.0%) patients who were operated under local anaesthesia. Postoperatively, dexamethasone was used in 117 (32.0%) and recurrence was observed in 17 (4.6%) patients (Table-3). The recurrences were managed by aspiration through the previous burr hole in eleven while only six patients required second burr

**Table-1:** Characteristics of the study population

Study population	N (%)
Age <18 years	10 (2.6)
Age >18 years but GA used	12 (3.0)
Single burr hole drainage under LA	365 (94.3)
Total patients	387 (100)

hole and nobody needed a third or more invasive surgery (Table-4).

The other complications that occurred in our patients were superficial wound infection in four cases (1.0%), subdural empyema and intracerebral hematoma in one case each. The patient who developed subdural empyema was treated successfully by craniotomy and antibiotic while the former patient got better with antibiotics alone. The intracerebral hematoma was caused iatrogenically by the insertion of red rubber catheter during subdural irrigation. Fortunately, the patient recovered well and needed no further surgical interventions. By the ends of three weeks, 360 (98.6%) had favorable outcome while five patients (1.4%) who were in coma at the time of presentation died (Table-5).

**DISCUSSION**

CSDH is one of the commonest neurosurgical conditions, yet controversy persists regarding treatment methods.<sup>5</sup> The spectrum of surgery extends from twist drill craniostomy to a more aggressive craniotomy and membranectomy. Burr hole drainage appears to occupy the position in between.

Twist drill craniotomy (TDC) is one of the three principal techniques used to treat chronic subdural hematoma, the other two being craniotomy and burr hole craniostomy. The advantage of this procedure is that it can be at the bedside quickly in frail, medically unfit, or very elderly individuals.<sup>6</sup> However, the recurrence rate after this procedure was found to be significantly higher (3-76%) than that of craniotomy or burr hole craniostomy (p<0.001).<sup>7</sup>

**Table-2:** Clinical presentation

Findings	N (%)
Altered level of consciousness	241 (66)
Focal neurological deficits	183 (50)
Documented trauma	201 (55)
Bilateral hematoma	49 (13)
Seizure	12 (3.3)
Coma	5 (1.4)
Quadriplegia	2 (0.54)

Craniotomy is often indicated in case with solid clots, thick outer membrane, multiple locations and recurrent intractable hematoma.<sup>8</sup> However, craniotomy with membranectomy is not necessary and is now reserved for instances of acute rebleeding with solid hematoma.<sup>9</sup> Moreover, Sambasivan did not report the need of a membranectomy even in large series of 2300 cases.<sup>10</sup> Comparison of burr hole, twist drill craniostomy and craniotomy revealed no difference in mortality.<sup>7</sup> However, craniotomy has significantly greater associated morbidity than the other two principal techniques.<sup>7</sup> The obvious question is why should craniotomy be performed if burr hole drainage is quicker and technically less demanding?<sup>5</sup>

BHD has been the standard treatment since McKissock et al published a large series in 1960.<sup>11</sup> This is a simple and widely practiced technique and has the best cure to complication ratio.<sup>7</sup> Most authors prefer to place two or three burr holes on the side of the lesion.<sup>2,6,12,13</sup> However, we choose to put a single burr hole on the common logic that multiple burr holes with the inevitable increase in operative time and surgical trauma will have inherent risk of increasing surgical complications. Moreover, a single dependent burr hole can address all the requirements of surgical exposure, namely adequate drainage, breakdown of septa and washing out of subdural space.<sup>14,15,16,25</sup>

Although the evidence for the benefit of irrigation in burr hole craniostomy is less strong, subdural space was irrigated thoroughly intra operatively in the present study as it is assumed that the irrigation washes out or at least dilutes the profibrinolytic compounds and angiogenic stimulators like vascular endothelial growth factors (VEGF). The subdural irrigation was thought to be more important in the present study since postoperative drains were not put of any kind. Neurosurgeons are divided in the issue of postoperative drainage and neurosurgical literature do not have class I evidence to favour the need of a postoperative drain. While many authors recommended it in the form of closed system drainage<sup>9,17-22</sup> or continuous drainage<sup>23,24</sup> or closed system suction drainage,<sup>25</sup> postoperative drains of any kind were not used in the present study.

**Table-3:** Complications of single burrhole drainage under local anaesthesia

Type of complications	N (%)
Recollection	17 (4.6)
Intracerebral hematoma	1 (0.3)
Superficial wound infection	4 (1)
Subdural empyema	1 (0.3)

**Table 4:** Description of procedures for complications

Procedures	N
Total number of surgery under LA	365
Recurrence	17
Aspiration through previous burrhole	11
Three or more aspirations	0

Recurrence rate of burr hole craniostomy has been reported in the literature in the range of 0-28.0%.<sup>7</sup> However, re-evacuation was possible in the majority through the same burr hole<sup>7</sup>. Present series with the recurrence rate of 4.6% had successful re-evacuation in 65.0% by needle aspiration through the same burr hole. Remaining 35.0% needed another burr hole because the previous one was found to be non dependent. Moreover, nobody needed more invasive surgery like craniectomy or craniotomy.

Operative mortality reported from 15.0% to 50.0% in the first half of the 20<sup>th</sup> century dropped significantly in the second half.<sup>8,11,14,15,18,23,24,26,27</sup> However, the mortality still varies widely between 0% and 11.0% and the morbidity varies between 0% to 25.0%. The present series with a mortality of 1.4% and morbidity of 6.3% compares well with the contemporary surgeries for chronic subdural haematoma. Neurological condition at the time of admission and the age of the patient appear statistically significant factors determining the outcome.<sup>18,25,27</sup>

Five patients who died in our series were all comatose at the time of presentation and were in their sixties. Incidentally though, all those over the age of 70 had presented in better neurological status and got an eventual recovery. Use of local anaesthesia not only eliminates the complications of general anaesthesia but also make the subsequent neurological assessment easy in immediate postoperative period with significant improvement occasionally noticeable right on the

**Table 5:** Outcome using Dichotomised Glasgow outcome scale


Outcome	Number
Favourable	360 (98.6%)
Unfavourable	5 (1.4%)
Total	365

operating table. Concomitant use of dexamethasone, rather liberal in this series (32.0%), follows the logic put forwarded by the advocates of the conservative treatment.

To conclude the present study shows that single burr hole drainage under local anaesthesia without using a postoperative drain appears sufficient in majority of patients. Only few patients require further drainage and that too can be done by needle aspiration through the previous burr hole in the majority. The outcome is favorable even in the elderly, provided they present before lapsing into coma. However, a well-designed prospective randomized trial is needed to back up this finding.<sup>5</sup>

**REFERENCES**

1. Virchow R. Das Hamatom der Dura mater. Verh Phys Med Ges Wurzburg 1857; 7: 134-42.
2. Kaye AH. Essentials of Neurosurgery 2<sup>nd</sup> ed. Singapore: Longman Singapore publishers; 1997; 87-90.
3. Tabaddor K, Shulmon K. Definitive treatment of chronic subdural hematoma by twist-drill craniostomy and closed-system drainage. *J Neurosurg* 1977; 46:220-6.
4. Hamilton MG, Frizell JB, Tranmer BI. Chronic subdural hematoma: the role for craniotomy reevaluated. *Neurosurg* 1993; 33: 67-72.
5. Santarius T, Hutchinson PJ. Chronic subdural haematoma: time to rationalize treatment? *Brit J Neurosurg* 2004; 18: 328-32.
6. Prabhu SS, Zauner A, Bullock MRR. Surgical management of traumatic brain injury. In Winn HR, editor. Youmans Neurological Surgery. 5<sup>th</sup> ed. Philadelphia: Saunders, 2004: 5145-80.



**Fig-1:** Sex distribution of the study patients

and the perinatal mortality can reach 80.0%. About 60.0% of fetuses die intrauterine, 30.0% show intrauterine growth retardation, and 25.0% thrombocytopenia.

## **THERAPY**

The management of patients with pre-eclampsia and HELLP syndrome is controversial. Most therapeutic modalities are similar to those applied for severe pre-eclampsia. Treatment should be performed in Intensive Care Units (ICU) with dialysis and ventilatory support in severe cases, and consists of plasma expanders, antithrombotic agents, heparin, antithrombin, aspirin in low doses, prostacyclin, immunosuppressive agents, steroids, fresh frozen plasma, dialysis.

The administration of corticosteroids is followed by a rapid improvement of clinical and laboratory parameters, allowing the delay of delivery. The improvement of thrombocytopenia has been more frequently observed for the low doses compared to the high doses.<sup>9</sup> However steroid therapy should only be administered to very well selected cases, since it does not improve prognosis.<sup>10-13</sup>

Plasmapheresis with fresh frozen plasma has been proposed as a therapeutic method in patients who show a progressive increase in bilirubinemia, serum creatinine, and have severe thrombocytopenia. This is also recommended for patients in whom HELLP syndrome persists for more than 72 hours postpartum, but has no favorable results in patients with fulminant hemolysis.<sup>14</sup>

Hypertension in preeclampsia can be treated with i.v. magnesium sulfate, hydralazine, calcium channel antagonists, and nitroglycerine or sodium nitroprusside (in hypertensive crisis). Diuretics are not used as a routine because they increase maternal hypovolemia and worsen uteroplacental hypoperfusion.<sup>2</sup>

## **OBSTETRIC APPROACH**

The induction of delivery is the only specific therapy in HELLP syndrome. In pregnant women with a gestational age of more than 34 weeks, immediate induction of delivery is recommended. Severe maternal complications are more frequent when the induction of pregnancy is delayed for more than 12 hours.<sup>15</sup> At a gestational age between 24-34 weeks, the use of corticosteroids to accelerate fetal pulmonary maturity, to reduce the risk of necrotic hemorrhagic rectocolitis and intraventricular hemorrhage of the fetus.

If no obstetric complications are present, vaginal delivery is preferred. Delivery by cesarean section is required in 60.0% of cases. In the case of cesarean section, subfascial drainage may be necessary in order to reduce the risk of hematomas.

Epidural anesthesia can be recommended when the thrombocyte count is higher than 100,000/mm<sup>3</sup>, when there are no coagulation disorders and the bleeding time is normal.<sup>16</sup>

## **SURGICAL APPROACH**

The rupture of a subcapsular liver hematoma followed by shock represents a surgical emergency. Massive blood transfusions and the correction of coagulopathy with fresh frozen plasma and thrombocyte mass are mandatory.<sup>17</sup> Immediate laparotomy is recommended. The options are: surgical ligation of the hemorrhagic hepatic segment, suture and drainage, suture of the omentum, surgical mesh at the level of the liver in order to improve its integrity.<sup>17</sup> Emergency surgical intervention should be performed if the patient shows hemodynamic instability, massive blood loss, increasing pain or hematoma infection.

The use of argon coagulation for hemostasis after the rupture of liver hematoma has been reported. Administration of recombinant F VIIa might suppress the hemorrhage and save the patient's life in cases that do not respond to surgical treatment.<sup>18</sup>

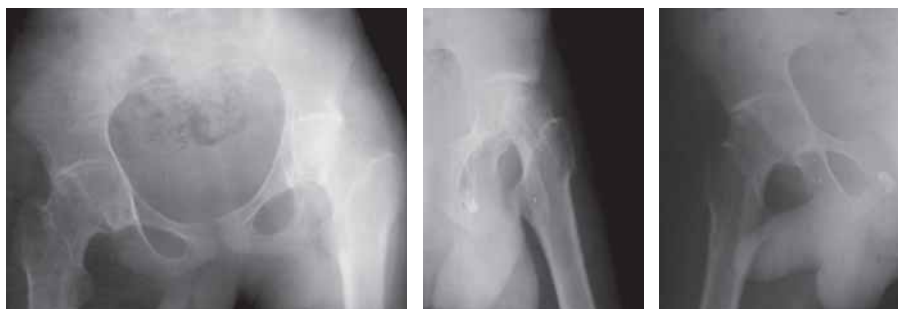**Follow up:** Repeated lists of platelet count and LDH serum concentration until platelet count is increased to >100,000/mm<sup>3</sup> and effective diuresis is achieved.

**Counseling for future pregnancy:** The use of low dose aspirin (80mg/day) is recommended from early in pregnancy to 36 wks in patients with previous HELLP syndrome, particularly if it was virulent or complicated.

HELLP syndrome is due to a generalized microangiopathy usually occurring in older multiparous women in the third trimester of pregnancy, which develops with focal liver involvement, hemolysis and thrombocytopenia. Hepatic (rupture), cerebral (hemorrhage) and DIC complications are severe and are associated with a high maternal death rate and important perinatal mortality.

## **REFERENCES**

1. Sibai BM. Diagnosis, controversies, and management of the syndrome of hemolysis, elevated liver enzymes, and low platelet count. *Obstet Gynecol* 2004; 103: 981-91.
2. Rahman TM, Wendon J. Severe hepatic dysfunction in pregnancy. *Queensland J Med* 2002; 95: 343-57.
3. Zhou Y, McMaster M, Woo K *et al.* Vascular endothelial growth factor ligands and receptors that regulate human cytotrophoblast survival are dysregulated in severe preeclampsia and hemolysis, elevated liver enzymes, and low platelets syndrome. *Amer J Pathol* 2002; 160: 1405-23.
4. Noris M, Todeschini M, Cassis P *et al.* L-arginine depletion in preeclampsia orients nitric oxide synthase toward oxidant species. *Hypertension* 2004; 43: 614-22.
5. Kawabata I, Nakai A, Takeshita T. Prediction of HELLP



**Fig. 7.** Pelvis with both hips AP and bilateral hips lateral view: shows tilted pelvis, reduced and incongruent hip joint spaces with malunited femoral physis, widened neck and tilted femoral head along with visible physeal scan on both sides.

The most important priority in the management of a patient with a SCFE is to prevent progression of the slip and avoiding the complications of avascular necrosis and chondrolysis.<sup>37</sup> The current treatment methods for a patient with a stable (chronic) SCFE include: (1) immobilization in a hip-spica cast<sup>38</sup> (2) in situ stabilization with single or multiple pins or screws<sup>39,40</sup> (3) open epiphyseodesis with iliac crest or allogeneic bone graft<sup>41,42</sup> (4) open reduction with a corrective osteotomy through the physis and internal fixation with use of multiple pins<sup>43,44</sup> (5) compensating base-of-neck osteotomy with in situ stabilization of the slipped capital femoral epiphysis with use of multiple-pin fixation<sup>45</sup> and (6) intertrochanteric osteotomy with internal fixation.<sup>46</sup>

The treatment of an unstable SCFE (acute or acute-on-chronic) is similar to that of a stable but is considerably more controversial. The role of immediate reduction compared with delayed reduction is controversial, as is the role of preoperative traction. Loder<sup>32</sup> compared the results of treatment in 25 hips that had a stable SCFE with those in thirty hips that had an unstable SCFE. The result was satisfactory in 96 percent of the 25 hips that had a stable and in 47 percent of the 30 hips that had an unstable. Lim<sup>47</sup> recommended straight leg traction for six weeks followed by in situ screw fixation without manipulation, due to a higher avascular necrosis risk for unstable SCFE.

Avascular necrosis (AVN) is a serious complication of SCFE and the treatment is difficult.<sup>48</sup> The complication of AVN is rare in patients with a stable SCFE, but frequent in patients with an unstable SCFE.<sup>32</sup> The factors responsible for the development of AVN are an acute unstable SCFE, over reduction, attempts at reduction of the chronic component of an acute-on-chronic SCFE, placement of pins in the superolateral quadrant of the femoral head, and femoral neck osteotomy.<sup>49,50</sup> The reported incidence varies from three to 47 percent of patients and all cases of AVN after SCFE are radiographically apparent within one year.<sup>51</sup> The treatment of AVN is not rewarding for the patient and the clinician. NWBCW, ROM exercises, and anti-

inflammatory medication may help to minimize symptoms. An internal fixation device that protrudes into the hip joint should be backed out of the joint or removed, if the physis is closed minimize symptoms and epiphyseal collapse. In severe cases, a hip arthrodesis or joint arthroplasty may be needed.<sup>29</sup>

Chondrolysis, the etiology is still unknown, is another major complications of SCFE and its prevalence increases with the increasing severity, is reported incidence of five to seven percent.<sup>52</sup> The diagnosis is confirmed by radiographs that demonstrate a decrease in the width of the joint space of greater than 50 percent compared with the uninvolved side or, in patients who have bilateral involvement, a joint space of less than three millimeters. The prognosis and the treatment are as of AVN.<sup>29</sup>

#### REFERENCES

1. Goodman DA, Feighan JE, Smith AD. Subclinical slipped capital femoral epiphyses: Relationship to osteoarthritis of the hip. *J Bone Joint Surg Amer* 1997; 79: 1489-93.
2. Jerre T, Karlsson J, Henrikson B. Incidence of physiolyis of the hip: A population based study. *Acta Orthop Scand* 1996; 67: 53-6.
3. Schein AJ. Acute severe slipped capital femoral epiphysis. *Clin Orthop Relat Res* 1967; 51: 151-66.
4. Segal LS, Weitzel PP, Davidson RS. Valgus slipped capital femoral epiphysis: fact or fiction? *Clin Orthop Relat Res* 1996; 322: 91-8.
5. Bright R, Burstein A, Elmore S. Epiphyseal plate cartilage: a biomechanical and histological analysis of failure modes. *J Bone Joint Surg Amer* 1974; 56: 688-93.
6. Ippolito E, Michelson M, Ponseti I. A histochemical study of slipped capital femoral epiphysis. *J Bone Joint Surg Amer* 1981; 63: 1109-12.
7. Kelsey JL, Keggi KJ, Southwick WO. The incidence and distribution of slipped capital femoral epiphysis in Connecticut and southwestern United States. *J Bone Joint Surg Amer* 1970; 52: 1203-16.
8. Kamarulzaman MA, Abdul Halim AR, Ibrahim S. Slipped capital femoral epiphysis (SCFE): a 12-year review. *Med J Malaysia* 2006(Suppl A); 61: 71-8.
9. Ninomiya S, Nagasaka Y, Tagawa H. Slipped capital femoral epiphysis. A study of 68 cases in the eastern half area of Japan. *Clin Orthop Relat Res* 1976; 119: 172-6.
10. Hansson LI, Häggglund G, Ordeberg G. Slipped capital femoral epiphysis in southern Sweden 1910-1982. *Acta Orthop Scandinavica* 1987 (Suppl); 226: 1-67.
11. Kelsey JL, Acheson RM, Keggi KJ. The body build of patients with slipped capital femoral epiphysis. *Amer J Dis Child* 1972; 124: 276-81.
12. Loder RT. The demographics of slipped capital femoral epiphysis. An international multicenter study. *Clin Orthop Relat Res* 1996; 322: 8-27.

13. Weiner D. Pathogenesis of slipped capital femoral epiphysis: current concepts. *J Pediatr Orthop B* 1996; 5: 67-73.
14. Pritchett JW, Perdue KD. Mechanical factors in slipped capital femoral epiphysis. *J Pediatr Orthop* 1988; 8: 385-8.
15. Galbraith RT, Gelberman RH, Hajek PC *et al.* Obesity and decreased femoral anteversion in adolescence. *J Orthop Res* 1987; 5: 523-8.
16. Gelberman RH, Cohen MS, Shaw BA, Kasser JR, Griffin PP, Wilkinson RH. The association of femoral retroversion with slipped capital femoral epiphysis. *J Bone Joint Surg Amer* 1986; 68: 1000-7.
17. Mirkopoulos N, Weiner DS, Askew M. The evolving slope of the proximal femoral growth plate relationship to slipped capital femoral epiphysis. *J Pediatr Orthop* 1988; 8: 268-73.
18. Exner GU. Growth and pubertal development in slipped capital femoral epiphysis: a longitudinal study. *J Pediatr Orthop* 1986; 6: 403-9.
19. Morscher E. Strength and morphology of growth cartilage under hormonal influence of puberty. Animal experiments and clinical study on the etiology of local growth disorders during puberty. *Reconstr Surg Traumat* 1968; 10: 3-104.
20. Spero CR, Masciale JP, Tornetta P, Star MJ, Tucci JJ. Slipped capital femoral epiphysis in black children: incidence of chondrolysis. *J Pediatr Orthop* 1992; 12: 444-8.
21. Harris WR. The endocrine basis for slipping of the upper femoral epiphysis: an experimental study. *J Bone Joint Surg Brit* 1950; 32: 5-11.
22. Sørensen K H. Slipped upper femoral epiphysis. Clinical study on aetiology. *Acta Orthop Scandinavica* 1968; 39: 499-517.
23. Aadalen RJ, Weiner DS, Hoyt W, Herndon CH. Acute slipped capital femoral epiphysis. *J Bone Joint Surg Amer* 1974; 56: 1473-87.
24. Boyer DW, Mickelson MR, Ponseti IV. Slipped capital femoral epiphysis. Long-term follow-up of one hundred and twenty-one patients. *J Bone Joint Surg Amer* 1981; 63: 85-95.
25. Ward WT, Stefko J, Wood KB, Stanitski CL. Fixation with a single screw for slipped capital femoral epiphysis. *J Bone Joint Surg Amer* 1992; 74: 799-809.
26. Ponseti I, Barta CK. Evaluation of treatment of slipping of the capital femoral epiphysis. *Surg Gynec Obstet* 1948; 86: 87-97.
27. Fahey JJ, O'Brien ET. Acute slipped capital femoral epiphysis. Review of the literature and report of ten cases. *J Bone Joint Surg Amer* 1965; 47: 1105-27.
28. Loder RT, Aronson DD, Greenfield ML. The epidemiology of bilateral slipped capital femoral epiphysis. A study of children in Michigan. *J Bone Joint Surg Am* 1993; 75: 1141-7.
29. Loder RT, Aronsson DD, Dobbs MB, Weinstein SL. Instructional Course Lectures: Slipped Capital Femoral Epiphysis. *J Bone Joint Surg Amer* 2000; 82: 1170-88.
30. Rab GT. The geometry of slipped capital femoral epiphysis: implications for movement, impingement, and corrective osteotomy. *J Pediatr Orthop* 1999; 19: 419-24.
31. Hanlon D, Evans T. The Hip and Proximal Femur. In: Schwartz DT, Reisdorff EJ, editors. *Emergency Radiology*. McGraw-Hill 2000: 217-42.
32. Loder RT, Richards BS, Shapiro PS, Reznick LR, Aronson DD. Acute slipped capital femoral epiphysis: the importance of physeal stability. *J Bone Joint Surg Amer* 1993; 75: 1134-40.
33. Kallio PE, Paterson DC, Foster BK, LeQuesne GW. Classification in slipped capital femoral epiphysis. Sonographic assessment of stability and remodeling. *Clin Orthop Relat Res* 1993; 294: 196-203.
34. Kallio PE, Mah ET, Foster BK, Paterson DC, LeQuesne GW. Slipped capital femoral epiphysis. Incidence and assessment of physeal instability. *J Bone Joint Surg Brit* 1995; 77: 752-5.
35. Steel HH. The metaphyseal blanch sign of slipped capital femoral epiphysis. *J Bone Joint Surg Amer* 1986; 68: 920-2.
36. Klein A, Joplin RJ, Reidy JA, Hanelin J. Slipped capital femoral epiphysis. Early diagnosis and treatment facilitated by "normal" roentgenograms. *J Bone Joint Surg Amer* 1952; 34: 233-9.
37. Aronson DD, Peterson DA, Miller DV. Slipped capital femoral epiphysis: the case for internal fixation in situ. *Clin Orthop Relat Res* 1992; 281: 115-22.
38. Betz RR, Steel HH, Emper WD, Huss GK, Clancy M. Treatment of slipped capital femoral epiphysis. Spica cast immobilization. *J Bone Joint Surg Amer* 1990; 72: 587-600.
39. Strong M, Lejman T, Michno P, Sulko J. Fixation of slipped capital femoral epiphyses with unthreaded 2-mm wires. *J Pediatr Orthop* 1996; 16: 53-5.
40. Ward WT, Stefko J, Wood KB, Stanitski CL. Fixation with a single screw for slipped capital femoral epiphysis. *J Bone Joint Surg Amer* 1992; 74: 799-809.
41. Rao SB, Crawford AH, Burger RR, Roy DR. Open bone peg epiphysiodesis for slipped capital femoral epiphysis. *J Pediatr Orthop* 1996; 16: 37-48.
42. Weiner DS, Weiner S, Melby A, Hoyt WA. A 30-year experience with bone graft epiphysiodesis in the treatment of slipped capital femoral epiphysis. *J Pediatr Orthop* 1984; 4: 145-52.
43. DeRosa GP, Mullins RC, Kling TF. Cuneiform osteotomy of the femoral neck in severe slipped capital femoral epiphysis. *Clin Orthop Relat Res* 1996; 322: 48-60.
44. Velasco R, Schai PA, Exner GU. Slipped capital femoral epiphysis: a long-term follow-up study after open reduction of the femoral head combined with subcapital wedge resection. *J Pediatr Orthop B* 1998; 7: 43-52.
45. Barmada R, Bruch RF, Gimbel JS, Ray RD. Base of the neck extracapsular osteotomy for correction of deformity in slipped capital femoral epiphysis. *Clin Orthop Relat Res* 1978; 132: 98-101.
46. Southwick WO. Osteotomy through the lesser trochanter for slipped capital femoral epiphysis. *J Bone Joint Surg Amer* 1967; 49: 807-35.
47. Lim YJ, Lam KS, Lim KBL, Mahadev A, Lee EH. Management outcome and the role of manipulation in slipped capital femoral epiphysis. *J Orthop Surg (Hong Kong)* 2007; 15: 334-8.
48. Uglow MG, Clarke NMP. The management of slipped capital femoral epiphysis. *J Bone Joint Surg Brit* 2004; 86: 631-5.
49. Krahn TH, Canale ST, Beaty JH, Warner WC, Lourenço P. Long-term follow-up of patients with avascular necrosis after treatment of slipped capital femoral epiphysis. *J Pediatr Orthop* 1993; 13: 154-8.
50. Carney BT, Weinstein SL, Noble J. Long-term follow-up of slipped capital femoral epiphysis. *J Bone Joint Surg Amer* 1991; 73: 667-74.
51. Mullins MM, Sood M, Hashemi-Nejad A, Catterall A. The management of avascular necrosis after slipped capital femoral epiphysis. *J Bone Joint Surg Brit* 2005; 87: 1669-74.
52. Mandell GA, Keret D, Harcke HT, Bowen JR. Chondrolysis: detection by bone scintigraphy. *J Pediatr Orthop* 1992; 12: 80-5.