

Patients with tonsil problems at NMCTH- a report

AK Jha and S Sharma

Department of Otorhinolaryngology, Nepal Medical College Teaching Hospital, Jorpati, Kathmandu, Nepal

Corresponding author: Dr. Anil Kumar Jha, Associate professor, Department of Otorhinolaryngology, Nepal Medical College Teaching Hospital, Jorpati, Kathmandu, Nepal, e-mail: dranilkumarjha@yahoo.com

ABSTRACT

The study was carried out in the Department of Otorhinolaryngology NMCTH (n=20, age 3-54yrs) who presented tonsil problems and underwent tonsillectomy over period of 1 year (2006-2007). Patients who underwent tonsillectomy were selected for study throughout preoperative and two months of postoperative period. Out of 20 patients (8 male and 12 female) 3 patients presented with sleep apnoea syndrome, 8 patients required hospitalization due to odynophagia and high fever and 9 of them suffered from recurrent tonsillitis. Post operative period was uneventful. The commonest presentation was recurrent sore throat and commonest organism isolated on throat swab culture (superficial) was *S. aureus* (26.0%). Sixty-nine percentage of culture was sterile, most probably because of prior antibiotics use. Only one out of twenty cultures showed \hat{a} haemolytic streptococcus. According to previous studies carried out, organism obtained from superficial swab may be different from that of from core and there were some differences between children and adults. \hat{a} haemolytic streptococci was the commonest organism (38.0%) isolated from surface.

Keywords: Tonsillitis, tonsillectomy.

INTRODUCTION

Palatine tonsils commonly called as tonsils are an ovoid mass of lymphoid tissue situated in lateral wall of oropharynx between anterior and posterior pillars. There are 3 types of tonsillitis:^{1,2} acute, subacute and chronic. Acute tonsillitis is managed medically. Recurrent tonsillitis means 4 or more documented attacks of tonsillitis associated with fever, tonsillar exudates and cervical lymphadenitis.¹ Recurrent tonsillitis is absolute indication of tonsillectomy.^{3,4} Other absolute indications are upper airway obstruction, peritonsillar abscess and suspicion of malignancy. In case of peritonsillar abscess patient must be judged for the need of tonsillectomy.^{5,6} Patient with repeated attacks of acute tonsillitis who develop peritonsillar abscess is in need of tonsillectomy more than those who had no previous attack of tonsillitis.^{7,8} Commonest organisms involved in tonsillitis are: haemolytic streptococcus, *S. aureus*, *H. influenzae* and pneumococci. Contraindications to surgery are bleeding disorders, recent infection. Complications of tonsillectomy include haemorrhage, Infection, lung complication, injury to adjacent structures, subacute bacterial endocarditis and postoperative pain.⁹⁻¹¹

PATIENTS AND METHODS

This is a prospective study carried out in the Department of Otorhinolaryngology, NMCTH over 1 yr period i.e 2006 to 2007. The patients presenting with tonsillitis were examined and cases that needed tonsillectomy and were willing to undergo surgery in our hospital were followed up.¹² Detail history about past episodes and the present complaints were noted and patient were followed up throughout pre operative and 2 months of

postoperative period. The age, sex, complications and throat swab culture reports were noted. Post operative follow up was also done.

RESULTS

In the present study out of 20 patients who underwent tonsillectomy - male to female ratio was found to be 2:3, the most common age at presentation was 15 to 25 yrs with 45.0% of patients belonging to this group. The commonest presentation was recurrent sore throat and commonest organism isolated on throat swab culture (superficial) was *S. aureus* (26 %). (Fig. 1) Sixty-nine percentage of culture was sterile. The commonest complication observed was peritonsillar abscess in 15.0% patients (Fig. 2).

Incidence of throat infection were reduced from average of 2-3 epsodes per month to one episode in 2-3 months.

DISCUSSION

The bacteriology of acute tonsillitis and peritonsillar abscess is different – and although one is a complication of the other, it may be that the complication only occurs in the presence on certain organisms.^{13,14} Although beta-haemolytic streptococcus is frequently isolated, it is rarely isolated on its own. In study by¹⁵ Gaffeny *et al* in core swabs mixed pathogens were isolated in most cases (48.0%) with commonest mixture being \hat{a} -hemolytic streptococci, *H. influenzae* and *S. aureus*. Anaerobes were found in 32.0% superficial swab and 5.0% core swab. In results from the naval medical centre, (1991) mixed aerobic and anaerobic flora were found in 76.0%. Beta-lactamase producing organism were recovered from 52.0% of swabs. In another study also

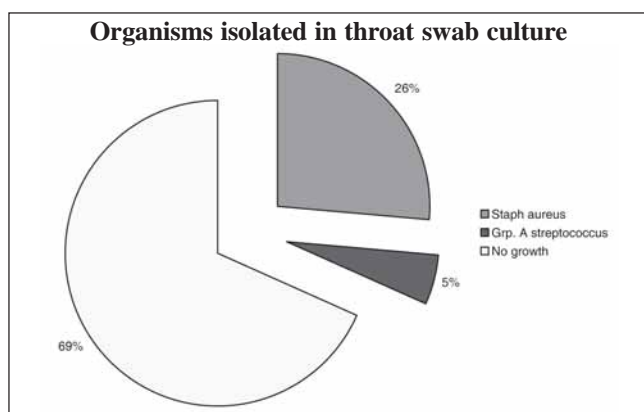


Fig. 1. Organisms isolated in throat swab culture

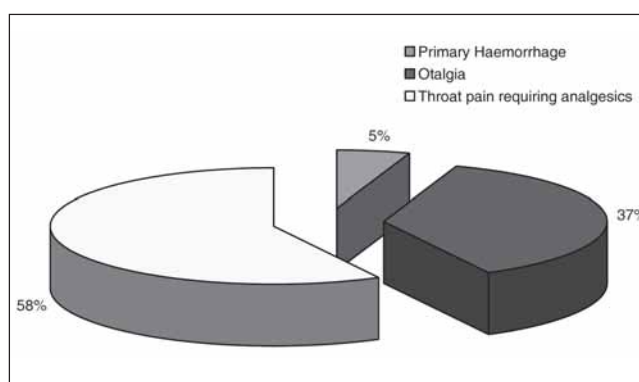


Fig. 3. Post- Operative complications during 1 week follow up period

demonstrated a large variety of different organisms in their series and it may be that the involvement on anaerobic organisms predisposes to infection spreading through the tonsillar capsule and much more frequent occurrence of peritonsillar abscess in adults.

In our study the commonest complication¹⁶ observed was peritonsillar abscess (15.0% of patients). Peritonsillar abscess is a collection of pus between the fibrous capsule of the tonsil, usually at its upper pole and the superior constrictor muscle of the pharynx. It usually occurs as a complication of acute tonsillitis. Though another 15.0% of patients suffered from sleep apnoea syndrome, it was not considered as complication of tonsillitis alone because they had adenoid hypertrophy along with enlarged tonsils. Tonsillectomy was the third common surgery done in Dept.of otorhinolaryngology, NMCTH, (13.3%). Peritonsillar abscess is a serious illness with a definite mortality. One who has repeated episodes of acute tonsillitis who then develops a quincy is perhaps in need of tonsillectomy. Commonest post operative complication seen¹⁷ was secondary haemorrhage which by definition, is any haemorrhage which occurs more than 24 hours after surgery and classically occurs at 6-8 days. Pain followed by otalgia which corroborates the previous observation reported. Episodes of throat infection were reduced from average of 2-3 episodes per month to 1 episode in 2-3 month. Our study showed that tonsillectomy prevents complications of tonsillitis.

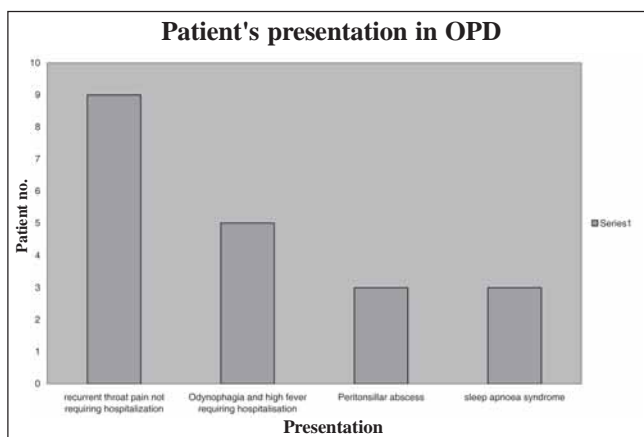


Fig. 2. Patient's presentation in OPD

REFERENCES

- Briden AC, Evans JN. Quincy tonsillectomy- a further report. *J Laryngol Otolology* 1970; 84: 443-8.
- Everett MT. The cause of tonsillitis. *Practitioner* 1979; 223: 253-9.
- Herbild O. and Bonding P. Peritonsillar Abscess recurrence rate and treatment. *Arch Otolaryngology* 1981; 107: 540-2.
- Harris WE. Is a single quincy an indication for tonsillectomy? *Clin Otolaryngol* 1991; 16: 271-3.
- Gafeney RJ, Preeman DJ, Walsh MA, Cafferkey MT. Differences in tonsils-a prospective study of 262 patients. *Respiratory Med* 1991; 85: 383-388.
- Jokinen K, Sipila P, Jokipii AMM, Jokipii L, Sorri M. Peritonsillar abscess, bacteriological investigation. *Clin otolaryngol* 2002; 10: 27-30.
- Paradise JL, Bluestone CD, Colborn Dk. Tonsillectomy for recurrent throat infection in moderately affected children. *Paediatr* 1998; 48: 1331-5.8. Marshall T. A review of tonsillectomy for recurrent throat infection. *Brit J General Practice* 1998; 48: 1331-5.
- Mosegaard Nielson V, Griesson J. Peritonsillar abscess cases treated with tonsillectomy a choud. *J Laryngolo Otol* 1981; 95: 801-7.
- Almadori G, Bastianini L, Bistonmi F, Paludetti G, Risugnoli M. Microbial flora of surface versus core tonsillar cultures in recurrent tonsillitis in children. *Int'l J Paediatr Otolaryngol* 1988; 15: 157-62.
- Ylikoski J, Karjalainen J. Acute tonsillitis in young men: etiological agents and their differentiation. *Scandinavian J Infect Dis* 1989; 21: 169-74.
- T. Butturo CG. Management of peritonsillar abscess at harare central hospital. *Central African Med* 1990; 30: 187-90.
- Brandon EC. Immediate tonsillectomy for peritonsillar abscess. *Transaction Amer Acad Ophthalmol Otolaryngol* 1973; 77: 412-6.
- Holt GR, Tinsley PP. Peritonsillar abscess in children. *Laryngoscope* 1981; 91: 1226-30.
- Kristenson S, Tveteras K. Post tonsillectomy haemorrhage and retrospective study of 1150 operations. *Clin Otolaryngol* 1984; 9: 347-50.
- Stage J, Jensen JH, Bonding P. Post tonsillectomy haemorrhage a comparative study of acetylsalicylic acid and paracetamol. *Clin Otolaryngol* 1990; 13: 201-4.
- Strunk CL, Nichols ML. A compatison of the KTP/532 laser tonsillectomy. *Otolaryngol Head Neck Surg* 1990; 103: 966-71.